



PATIENT

Honey Martinez

SPECIES

Canine

BREED

Chihuahua

SEX

Female Intact

AGE

11 years

WEIGHT

8.19lbs

INTERPRETED BY

Maggie Machen Lamy, DVM DACVIM (Cardiology)

IMAGING PERFORMED BY

Pamela Harrigan, RDCS

HOSPITAL NAME

Mass Veterinary Services

REFERRING VET

Dr. Masloski

INVOICE

27226

DATE

11/1/22

PRESENTING CLINICAL SIGNS

History: Recheck echo. History chronic valvular disease - Stage B1. Currently, Honey is doing well at home with a good appetite and activity level. On exam: NSR, grade II/VI murmur with PMI left apical area, PSS, lung fields clear. BP: 140mmHg x 5. *No sedation for study.

-Pertinent previous echo findings (9/7/21 Maggie Machen Lamy, DVM, DACVIM-Cardiology): LA 1.2 cm; LA:Ao 1.0; LV 1.8 cm; normal LA size; mild MR; trace TR (2.6 m/s).

ECHOCARDIOGRAM FINDINGS

2D, m-mode, color flow and Doppler imaging is available.

Left ventricle: The LV diameter is normal with adequate myocardial function. LV wall thicknesses are normal.

Left atrium: The left atrium is normal.

Mitral valve: The mitral valve is mildly thickened with minimal prolapse into the left atrial lumen. Mild double jet of eccentric mitral regurgitation.

Aortic valve/aorta: The aortic valve is normal in morphology and mobility. Normal aortic outflow velocity; laminar flow. No aortic insufficiency.

Right ventricle: Normal right ventricular diameter and morphology indicating no overt evidence of pulmonary arterial hypertension.

Right atrium: Normal RA dimension.

Tricuspid valve: The tricuspid valve appears normal with trace tricuspid regurgitation; normal velocity.

Pulmonic valve/pulmonary artery: The pulmonic valve is normal in morphology and mobility. No pulmonic insufficiency. Normal RVOT velocity; laminar flow.

Pericardium/other: No pericardial or pleural effusion noted. No obvious cardiac masses.

Heart rhythm: ECG reveals a sinus rhythm with an average HR of 130bpm.

2-Dimensional Measurements

Ao diam (cm)	1.3
LA diam (cm)	1.1
LA:Ao (Swe)	1.2
IVS thickness (cm)	0.5
LVID diastole (cm)	1.9
PW thickness (cm)	0.5
LVID systole (cm)	0.8
FS (%)	58

Doppler Measurements

PV Vmax (m/s)	0.88
AoV Vmax (m/s)	0.9
MR Vmax (m/s)	NM
TR Vmax (m/s)	2.5
TR PG (mmHg)	25

INTERPRETATION OF THE FINDINGS

Chronic degenerative valve disease persists with evidence of stability. Mild MR and TR are unchanged without progressive left or right heart enlargement. No additional issues are identified.

Continued assessment of progression in the future will help predict long term prognosis, which remains highly variable at this stage (B1).



PATIENT

Honey Martinez

SPECIES

Canine

BREED

Chihuahua

SEX

Female Intact

AGE

11 years

WEIGHT

8.19lbs

INTERPRETED BY

Maggie Machen Lamy, DVM
DACVIM (Cardiology)

IMAGING PERFORMED BY

Pamela Harrigan, RDCS

HOSPITAL NAME

Mass Veterinary Services

REFERRING VET

Dr. Masloski

INVOICE

27226

DATE

11/1/22

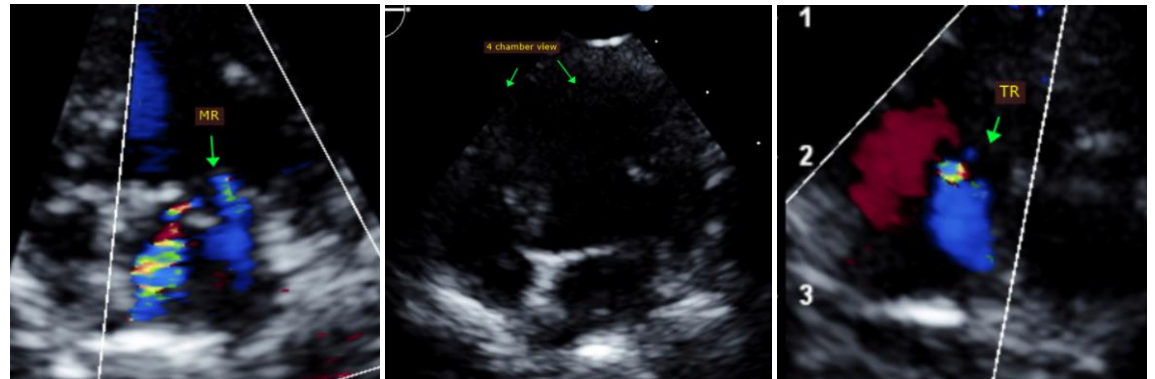
RECOMMENDATIONS

- No cardiac medications are clearly indicated.
- Omega fatty acid supplementation and mild salt restriction may be of some long-term benefit.
- Anesthetic risk is considered mild if needed. Cardiac protective drug choices (opioid/benzodiazepine premedication, propofol or alfaxalone induction, isoflurane gas) are recommended. Pre-oxygenate for 5-10 minutes prior to induction. Monitor for arrhythmias, hypotension, and hypoxia both intra and post-operatively and intervene as necessary. Mild IV fluid restriction is recommended to avoid fluid overload. Avoid heart rate stimulating drugs such as atropine unless clinically indicated.
- Monitor for development of a cough, labored breathing, exercise intolerance or collapse episodes.

PLAN

- Recommend conservative monitoring with a recheck echocardiogram in 1 year, sooner if any development of clinical signs.

IMAGES



The information and recommendations provided are based on the images presented by the referring veterinarian. No evaluation can be communicated regarding pathology that was not visible in the image/video clips provided.

Thank you for this referral. This report was generated using transcription software, and minor dictation errors may be present. If the clinical or image interpretation does not parallel your findings or if I can be of any further assistance, please contact me.

Maggie Machen Lamy, DVM
Diplomate of the American College of Veterinary Internal Medicine (Cardiology)
info@sonopath.com

Echocardiogram performed by: Pamela Harrigan, RDCS
Pet Animal Ultrasound Service (4paus.com)